Injury 56 (2025) 112857

Contents lists available at ScienceDirect

Injury

journal homepage: www.elsevier.com/locate/injury

Review

Acute pain management of rib fractures: a narrative review

Thomas Ulrich Bresgen [a,b], Francesco Salinaro [b,c], Bruno Barcella [b,c], Stefano Perlini [b,c], Ilenia Mascherona [d], Santi Di Pietro [e,f,*]

[a] Emergency Unit, Ospedale Maggiore Di Lodi, Italy
[b] Emergency Medicine Unit and Emergency Medicine Postgraduate Training Program, IRCCS Fondazione Policlinico San Matteo, Department of Internal Medicine, University of Pavia, Italy
[c] PhD Program in Experimental Medicine, University of Pavia, Italy
[d] Emergency Department, Ente Ospedaliero Cantonale (EOC), Ospedale Regionale di Lugano, Switzerland
[e] Emergency Medicine Research Unit, Department of Internal Medicine and Therapeutics, University of Pavia, Pavia, Italy
[f] Emergency Medicine Research Oxford (EMROx), Oxford University Hospital NHS Foundation Trust, UK

ARTICLE INFO

Keywords:
Rib fracture
Thoracic trauma
Pain management
Multimodal analgesia
Regional anesthesia
Emergency medicine

ABSTRACT

Background: Rib fractures are common conditions often associated with significant complications, including respiratory failure, pneumonia, prolonged hospitalisation, and chronic pain. Adequate pain management is crucial to improve outcomes and reduce morbidity in these patients. Despite the wide adoption of multimodal analgesia, the optimal combination of analgesic strategies remains uncertain.
Objective: To review and synthesize current evidence on analgesic strategies for acute pain management in patients with rib fractures.
Methods: We conducted a narrative review by searching scientific literature on PubMed and Scopus to identify randomised controlled trials (RCTs) on analgesia for rib fractures from blunt trauma. Included studies assessed pharmacologic, non-pharmacologic and regional anaesthesia interventions. Studies describing surgical treatment of multiple rib fractures or addressing analgesia for non-traumatic causes of rib fractures (e.g. neoplasms) or study design other than RCTs were excluded. Forty-seven RCTs met the inclusion criteria.
Results: Opioids remain the most studied class of analgesics in the context of rib fracture. While effective for acute pain relief, they pose significant risks, especially in the elderly population. Non-opioid agents - especially non-steroidal anti-inflammatory drugs (NSAIDs) and paracetamol –are effective components of opioid-sparing strategies. Thoracic epidural and paravertebral blocks offer superior analgesia and respiratory benefits but are associated with a steep learning curve, are time-consuming, and carry a significant risk of procedural complications. Emerging regional anaesthesia techniques, such as the erector spinae plane (ESP) and serratus anterior plane (SAP) blocks, demonstrated promising results due to their ease of administration and favourable safety profiles. Non-pharmacologic approaches, including cryotherapy, transcutaneous electrical nerve stimulation (TENS), and kinesiotaping, represent additional pain relief options, although evidence remains limited.
Conclusions: Multimodal analgesia - combining pharmacologic, non-pharmacologic and regional anaesthesia approaches –is considered the most effective strategy to guarantee pain relief in patients with multiple rib fractures. However, substantial heterogeneity remains in the regimens employed. Further research is needed to standardize multimodal analgesic protocols and to assess their impact on long-term, patient-centred outcomes.

Abbreviations

AIS	Abbreviated Injury Scale
EDs	Emergency Departments
ERAS	Enhanced Recovery After Surgery
ESPB	Erector Spinae Plane Block
ICNB	Intercostal Nerve Block
IM	Intramuscular
ISS	Injury Severity Score
IV	Intravenous
NRS	Numeric Rating Scale
NSAIDs	Non-steroidal Anti-inflammatory Drugs

* Corresponding author at: Dipartimento Medicina Interna e Terapia Medica, Viale Camillo Golgi 19 (Presso Campus della Salute), Pavia, 27100, Italy.
E-mail address: santi.dipietro@unipv.it (S. Di Pietro).

https://doi.org/10.1016/j.injury.2025.112857
Accepted 26 October 2025
Available online 5 November 2025
0020-1383/© 2025 The Author(s). Published by Elsevier Ltd. This is an open access article under the CC BY license (http://creativecommons.org/licenses/by/4.0/).

PCA	Patient Controlled Analgesia
PVB	Paravertebral Block
RCTs	Randomis ed Controlled Trials
SAPB	Serratus Anterior Plane Block
TEA	Thoracic Epidural Analgesia
TENS	Transcutaneous Electrical Nerve Stimulation
VAS	Visual Analog Scale

Introduction

Rib fractures are a common and remarkable cause of morbidity, frequently encountered in Emergency Departments (EDs) following a blunt thoracic trauma. They are often associated with complications such as pulmonary contusion, flail chest, pneumonia, haemothorax, pneumothorax, and respiratory failure, all of which contribute to increased hospital admissions, prolonged length of stay and increased healthcare costs [1]. Rib fractures are particularly prevalent among young adults sustaining major trauma as well as in older adults sustaining falls, with a rising incidence reported in recent years [2].

According to data from the United States National Trauma Database, between 2010 and 2016 over 560,000 cases of rib fractures were reported. The leading causes included motor vehicle collisions (over 50 %), falls (30 %), and other aetiologies [3]. Patients with rib fractures experience considerable morbidity and mortality with an average mortality rate of 5.6 %, increasing up to 10.2 % in cases of polytrauma involving other anatomical regions [2].

Acute pain - a hallmark of rib fractures –impairs effective coughing and clearance of pulmonary secretions, thereby increasing the risk of chest infections and respiratory failure [4]. In addition to that, poorly treated acute pain may evolve into chronic pain syndromes, further impacting the quality of life and increasing healthcare utilisation [5]. While multimodal pain management is generally regarded as a best practice for these patients, consensus on the optimal combination of strategies remains lacking [6].

This narrative review aims to describe and evaluate current evidence on the acute pain management of rib fractures.

Methods

A comprehensive literature search was performed on two databases, PubMed and Scopus, to identify randomised controlled trials (RCTs) that met the inclusion criteria. A detailed search strategy is provided as an appendix.

For PubMed, search terms included:

- “Rib fractures” OR “Rib injury” OR “Rib trauma” OR “Fracture ribs” OR “Thoracic trauma” OR “Flail chest”
- AND
- “Analgesia” OR “Pain management” OR “Pain relief” OR “Pain Reduction” OR OR “Analgesic agents” OR “Pain control”

For Scopus, the search terms were:

- “Rib fractures" OR "Rib injury" OR "Rib trauma" OR "Fracture ribs" OR "Thoracic trauma" OR "Flail chest"
- AND
- "Analgesia" OR "Analgesic" OR "Pain"
- AND
- "Randomised" OR "Randomisation" OR "RCT"

Between January 5th and February 5th, 2025, we searched the two databases covering all available records from inception through December 31st, 2024. Additionally, the reference lists of three relevant systematic reviews and meta-analyses were manually reviewed to identify further eligible studies [6–8].

Inclusion criteria

Eligible studies had to meet the following criteria:

- **Design:** Prospective RCTs with a control group (placebo or active comparator).
- **Language:** Published in English.
- **Population:** Patients with rib fractures resulting from blunt trauma.
- **Interventions:** Non-surgical analgesic strategies, including pharmacologic therapies, regional anaesthesia, non-pharmacological interventions, and multimodal approaches.

Exclusion criteria

The following studies were excluded:

- Studies focusing on surgical stabilization of rib fractures as the primary treatment strategy.
- Rib fractures due to penetrating trauma or pathological conditions (e.g. neoplasms, metabolic bone diseases).
- Observational studies or any study with a design other than RCT.

Data extraction

Two independent researchers conducted study selection and data extraction. A third researcher was asked to resolve any discrepancies or conflicts in the selection process.

Outcomes

The primary outcomes included:

- Pain intensity assessed using the Numeric Rating Scale (NRS) or Visual Analog Scale (VAS).
- Reduction in the use of opioids, other narcotics, or epidural infusions.
- Improvement in incentive spirometry performance.
- Reduction in rib fracture-related complication rate, including mortality and length of hospital stay

Synthesis methods

A meta-analysis was not performed. Instead, results were synthesized narratively by assessing the direction of effect, indicating whether each intervention showed benefits for any of the outcomes determined a priori.

We described the heterogeneity of patients across different studies by reporting the median or mean number of fractured ribs as well as the Injury Severity Score (ISS). If reported by authors, we also described other determinants of injury severity (e.g., flail chest, lung contusion, etc.).

Results

A comprehensive database search yielded a total of 956 articles (296 from Scopus and 660 from PubMed). Table 1 illustrates the flow diagram of the systematic review.

In Table 2, we provide a graphical summary of studies included in the review.

Pharmacological approaches

Opioids

Opioids are widely employed for acute pain management in rib fractures, typically administered intravenously (e.g. morphine, fentanyl) for their rapid effect. However, due to significant side effects -

Table 1
Flowchart of screened and included studies.

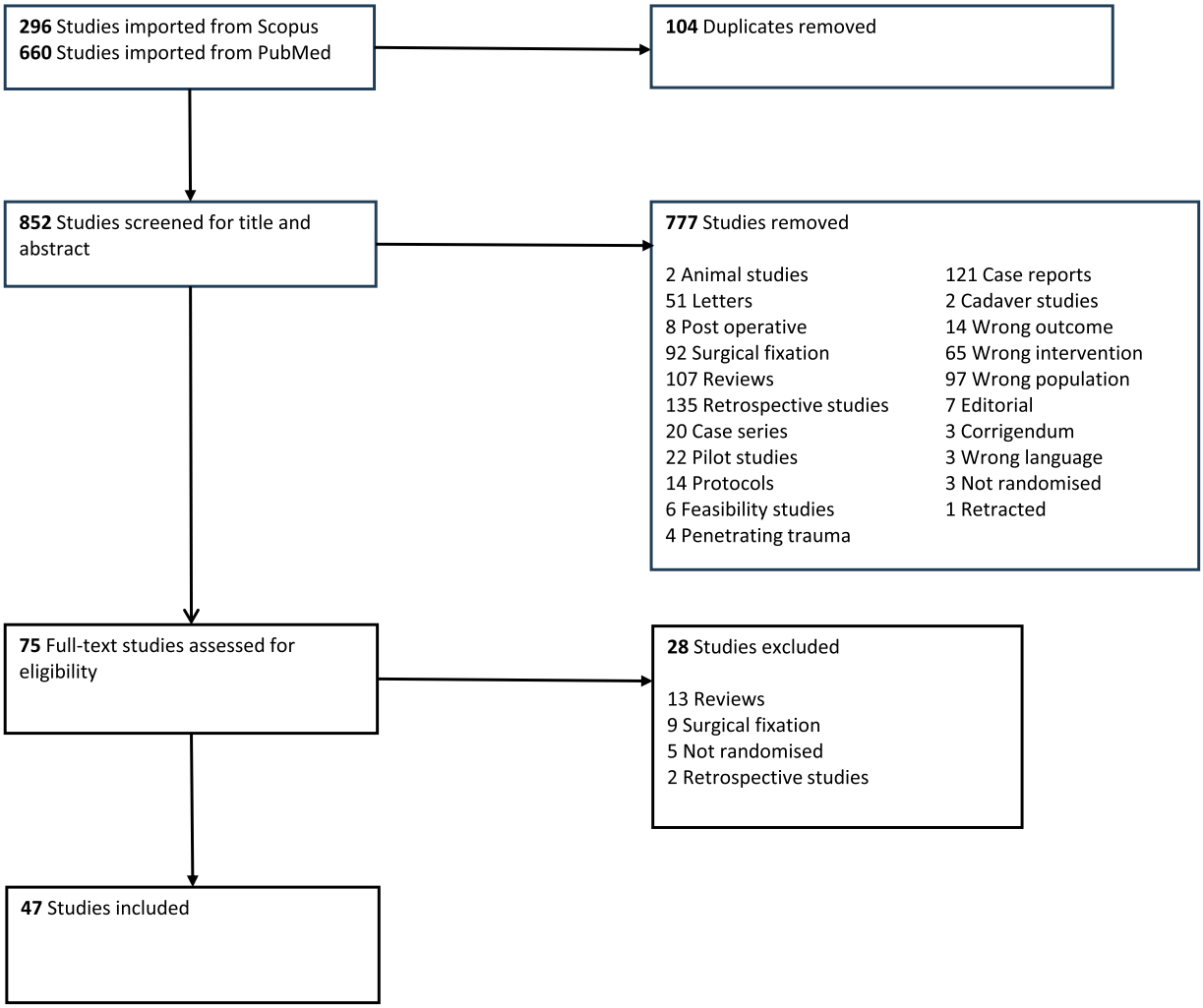

particularly respiratory depression - different routes of administration were investigated as well as opioid-sparing strategies.

Two studies examined different routes of administration for opioids:

- *Solak* et al. compared intravenous (IV) fentanyl with transdermal patches, both combined with intercostal nerve blocks and oral paracetamol, in a population with a mean of 5 rib fractures, and found comparable pain scores [9].
- *Fulda* et al. compared nebulized to IV morphine (via patient-controlled analgesia, PCA), both with potential IV morphine rescue doses, in patients with mean ISS scores of 10.5 and 9.8, respectively. Pain reduction and respiratory function improvement were similar, but opioid consumption was higher in the nebulized group [10].

Nonsteroidal anti-inflammatory drugs (NSAIDs) and paracetamol

NSAIDs were widely used as part of multimodal analgesic regimens. However, no studies were identified that evaluated NSAIDs as a singular modality intervention nor as a control arm.

Paracetamol is a commonly utilised non-opioid analgesic, often administered in combination with other agents within multimodal analgesia protocols. Due to its favourable safety profile and fewer adverse effects compared to NSAIDs, it is considered suitable for managing mild to moderate pain. Intravenous paracetamol has gained popularity for its rapid onset and efficacy in acute pain management.

We identified two trials that analysed the effect of IV Paracetamol:

- *Esmailian* et al. found comparable pain relief between IV Paracetamol and IV morphine, with rescue doses of IV morphine in both groups, in patients with one to two rib fractures [11].
- *Antill* et al. reported no significant differences between IV and oral Paracetamol, with potential rescue doses of opioids, in terms of pain reduction, opioid consumption, respiratory improvement or complication rates. The study included patients with a mean of 4.83 and 5.79 rib fractures in the IV and oral groups, respectively [12].

Gabapentinoids

One study analysed the effect of oral gabapentin (Neurontin). *Moskovitz* et al. compared the addition of oral gabapentin (Neurontin) to placebo, both within a standard analgesic regimen consisting of Paracetamol 650 mg four times daily, ibuprofen 600 mg four times daily, IV opioids, and rescue regional anaesthesia. The study included a population with median rib fractures counts of 7 and 5 and median ISS of 12

Table 2
Summary and main features of included studies.

				Outcomes compared to control					Injury severity		
Author	Intervention	Control group	Population	Overall benefit	Pain level	Opioid consumption	Lung function test	Complication rate	Mean n. rib fx	Injury severity score	
Opioid											
G.J. Fulda et alii	nebulized morphine + 5mg IV morphine + placebo IV + rescue 2mg IV morphine dose	IVPCA morphine + 5mg IV morphine + placebo inhalatory therapy + rescue 2mg IV morphine dose	44	~	=	incr ↑	=	/		10.5,9.8 iss	L/M
O Solak et alii	transdermal fentanyl 50mcg + ICNB & 500mg paracetamol 4x/d	pethidine IM 40mg 4x/d or fentanyl IV PCA + ICNB & paracetamol 500mg 4x/d	45	~	=	/	/	/	5(+2), 5(+1), 5 (+2) mean rfx		S
Acetaminophen											
M Esmailian et alii	IV acetaminophen 1g + rescue morphine	IV morphine sulfate (0.1mg/kg) + rescue morphine	54	~	=	/	/	/	1 or 2 rfx		L
AC Anaill et alii	IV acetaminophen 1g 4x/d + placebo PO + rescue opioids	Acetaminophen PO 1g + placebo IV + rescue opioids	138	~	=	=	=	=	4.83, 5.79 mean rfx		M
Oral analgesics											
E.E. Moskowitz et alii	Gabapentin PO + acetaminophen 650mg 4x/d & ibuprofen 600mg 4x/d + IV opioids + rescue regional anesthesia	placebo PO + acetaminophen 650mg 4x/d & ibuprofen 600mg 4x/d + IV opioids + rescue regional anesthesia	40	~	=	=	=	=	7[2-15], 5[3-12] median rfx	12[1-24], 16[4-34] mean iss	S
Intravenous treatment											
P. Patton et alii	IV Lidocaine + standard care (acetaminophen, NSAIDs, opioids)	placebo Ringer IV + standard care (acetaminophen, NSAIDs, opioids)	34	✔	red. ↓	=	/	=	5[5,8], 6[5,7] median rfx		S
NW Kugler et alii	IV Ketamine + standard care (NSAIDs, paracetamol, opioids) + rescue epidural	placebo IV 0.9% NaCl + standard care (NSAIDs, paracetamol, opioids) + rescue epidural	59	✔	=	red. ↓ (ISS> 15)	/	/	6.3 (+3.0) mean rfx	13[4,48] iss median	S
TW Carver et alii	IV ketamine + standard care (NSAIDs, paracetamol, opioids) + rescue epidural	placebo IV 0.9% NaCl + standard care (NSAIDs, paracetamol, opioids) + rescue epidural	91	✔	=	red. ↓ (ISS> 15)	/	/	6.4 (+3.2)mean rfx	14[9,38] iss med,	S
C Machado et alii	IV ketamine + paracetamol 1g 4x/d, ibuprofen 600mg 4x/d/ketorolac 7.5-15mg IV 4x/d, lidoderm 5% patches, oxycodone 5-10mg 6x/d OR hydromorphone 0.4-0.8mg every 2h, methocarbamol 500-1000mg 4x/d & rescue regional or epidural block	placebo IV + paracetamol 1g 4x/d, ibuprofen 600mg 4x/d/ketorolac 7.5-15mg IV 4x/d, lidoderm 5% patches, oxycodone 5-10mg 6x/d OR hydromorphone 0.4-0.8mg every 2h, methocarbamol 500-1000mg 4x/d & rescue regional or epidural block	50	~	/	=	/	=	5.7 (+1.9), 7.12(+ 3.8) mean rfx	15.1 (+5.1), 11.4 (+3.2) ISS mean	S
Adjunctive oral											
AMF Abdelwahman et alii	Melatonin PO + epidural infusion & IV diclofenac (1mg/kg) 3x/d & IV paracetamol 1g 3x/d + rescue 0.01mg/kg morphine IV	placebo PO + epidural infusion & IV diclofenac (1mg/kg) 3x/d & IV paracetamol 1g 3x/d + rescue 0.01mg/kg morphine IV	80	✔	=	red. ↓	/	/	3.17[-, 3.2 mean rfx		M
Topical treatment											
AB Erdem et alii	Lidocaine spray 10% + rescue tramadol or intercostal block	IV Tramadol100mg/kg V Fentanyl 50mcg + rescue tramadol or intercostal block	48	~	=	=	/	/	median 2 [2-3], 3[2-3], 3[2.5-3.0] rfx		L
S Dinome z et alii	Lidocaine spray + dexketoprofen IV & rescue tramadol	Etoforesmate spray/placebo + dexketoprofen IV & rescue tramadol	84	~	=	=	/	/	2[2-3], 3[2-3],2[1-3] median rfx		L
NK Ingalls et alii	Lidocaine patch + morphine IV 2-4mg per 2h & hydrocodone/acetaminophen PO 5/500mg 1-2 per 4h + rescue diluudid/fentanyl/ propoxyphene	placebo patch + morphine IV 2-4mg per 2h & hydrocodone/acetaminophen PO 5/500mg 1-2 per 4h + rescue diluudid/fentanyl/ propoxyphene	58	~	=	=	/	=	5.3(+0.4), 4.9(+0.4) mean rfx	17.3 (+1.3),17.9(+1.3) iss -	S
	naproxen/oxycodone	naproxen/oxycodone									
YJ Chong et alii	Lidocaine patch + ultracet (tramadol/paracetamol 37.5/325mg) every 6h + rescue ultracet every 6h or meperidine 50mg IM	placebo patch + ultracet (tramadol/paracetamol 37.5/325mg) every 6h + rescue ultracet every 6h or meperidine 50mg IM	44	✔	red. ↓	red. ↓	=	/	3.04(+1.2) , 3.0(+0.8) mean rfx		M
Epidural analgesia											
EM Bulger et alii	TEA	Opioids IV PCA (morphine, hydromorphone, fentanyl)	46	✔	/	/	/	red. ↓*	7.2 (+3.2), 6.8 (+3.3) mean rfx	26 (+8), 25(+8) mean ISS	S
M. R Moon et alii	TEA	morphine IV PCA	24	✔	red. ↓	/	impr ↑	/	1/more of 3 or more rfx, flail chest, pulmonary contusion or sternal fracture	26-6, 23.4 median ISS	S
DA Ullman et alii	TEA	morphine IV (1-1.5mg/h or 5mg 6x/d)	28	✔	/	=	impr ↑ (only TV)	/	7.33 (+0.56), 6.58 (+1.08) mean rfx	19.5 (+2.03), 25.3 (+2.89) mean ISS	S
SM Ahmed et alii	thoracic Epidural	IV fentanyl 2mcg/kg	20	✔	/	/	impr ↑	=	3-3 (+0.88), 4.1 (+1.1) mean rfx	25(+7), 28 (+7) mean ISS	S
S Heidari et alii	thoracic epidural	1g apotel IV (paracetamol)	84	✔	red. ↓	/	/	/	3-4 rfx		M
F-A Luchetti e	TEA + 0.1mg/kg morphine or meperidine IV 6x/d	Intrapleural block + 0.1mg/kg morphine or meperidine IV 6x/d	19	✔	red. ↓	red. ↓	impr ↑	/	3 or more similar rfx with flail segment	21.7 (+5.5), 19.4 (+5.7) mean ISS	S
A Kamali et alii	thoracic epidural	intercostal block	82	✔	red. ↓	/	/	=	3-4 rfx		M
								*adjusted to pulmonary contusion			
Paravertebral block											

(*continued on next page*)

Table 2 (*continued*)

G Teying et alii	PVB + 500mg acetaminophen PO 2x/d + rescue 1mg/kg tramadol	sufentanil IV PCA + 500mg acetaminophen PO 2x/d + rescue 1mg/kg tramadol	90	✔	red. ↓	/	imp r. ↑	/	3.9 (+1.2),4.1 (+1.4) mean rfx	14.2 (+5.1),13.7 (+5.5) mean iss	M
M Mohta et alii	PVB with fentanyl + 1mg/kg diclofenac IM 2x/d + rescue morphine IV	PVB with fem + 1mg/kg diclofenac IM 2x/d + rescue morphine IV	30	~	=	=	=	=	4.1 (+1.2), 3.9 (+1.1) mean rfx	13.3 (+4.6), 12.8 (+6.1) mean ISS	M
M Mohta et alii	PVB + 1mg/kg diclofenac IM or 1mg/kg tramadol IM + rescue morphine IV	TEA + 1mg/kg diclofenac IM or 1mg/kg tramadol IM + rescue morphine IV	30	~	=	=	=	=	4.9 (+1.4), 4.9 (+1.8) mean rfx	13.6 (+5.0), 15.9 (+7.1) mean ISS	M
Intrapleural analgesia												
SGA Gabra et alii	Intrapleural catheter	IV opioid	42	~	/	/	=	=	3.4, 4.4 mean rfx	13.5, 13.6 mean ISS	M
K Shah et alii	Intrapleural bupivacaine & lidocaine + IV meperidine or morphine.	Intrapleural saline + IV meperidine or morphine	16	~	=	=	=	/	N/A		N/A
K Shimah ara et alii	Intrapleural anesthetics + rescue 1mg IV butorphanol	epidural + rescue 1mg IV butorphanol	17	✔	=	=	/	=	5.7+-1.4 mean rfx		S
Intercostal nerve block												
TE Wallace et alii	Intercostal nerve block + standard care (acetaminophen, NSAIDs, transdermal lidocaine, IV/PO opioids, epidural analgesia)	placebo sulic injection + standard care (acetaminophen, NSAIDs, transdermal lidocaine, IV/PO opioids, epidural analgesia)	100	✔	=	=	imp r. ↑	=	7.28 (+3.59) mean rib fractures	17.76 (+7.38) mean iss	S
H Cifuci et alii	Intercostal nerve block + acetaminophen 500mg 2x/d & celecoxib 100mg 2x/d	acetaminophen 500mg 2x/d & celecoxib 100mg 2x/d	61	✔	red. ↓	/	/	/	3.13, 3.09 mean rfx		M
N Nasr-Esfahani et alii	Intercostal nerve block + rescue IV fentanyl	intrapleural block + rescue IV fentanyl	30	✔	red. ↓	red. ↓	/	/	N/A		N/A
S Hashemzadeh et alii	Intercostal nerve block + rescue pethidine 0.5mL	TEA + rescue pethidine 0.5mL	60	✕	incr. ↑	/	red. ↓	=	3 or more rfx		M
SAPB												
S Tekan et alii	SAPB + Tramadol IV PCA	Tramadol IV PCA	60	✔	red. ↓	red. ↓	/	/	N/A, post ant lat		N/A
A Elwafa et alii	SAPB	Morphine IV	40	✔	red. ↓	red. ↓	/	/	3-6 rfx, ant lat		M
C Parrado et alii	SAPB + standard care	standard care	210	✔	red. ↓	red. ↓	/	=	4 (2-5), 3(2-5) median rfx	AIS 92 1-2 and 115 3-5	M
AR Landers et alii	SAPB + paracetamol 1g 3x/d PO/IV & rescue IVPCA oxycodone	TEA + paracetamol 1g 3x/d PO/IV & rescue IVPCA oxycodone	59	✕	incr. ↑	=	red. ↓	=	5(+2), 5(+2) mean rfx	3(+0), 3(+0) mean AIS chest score	S
ESPB												
Sverlis Ramesh	ESPB + 100mg tramadol IV + 1g paracetamol IV + rescue 50mg tramadol IV & rescue 25mcg fentanyl IV	sham ESPB + 100mg tramadol IV + 1g paracetamol IV + rescue 50mg tramadol IV & rescue 25mcg fentanyl IV	46	✔	red. ↓	red. ↓	/	/	N/A		N/A
S Elmasry et alii	ESPB + rescue 0.05mg/kg IV morphine	IV morphine 0.1mg/kg & IVPCA morphine + rescue 0.05mg/kg IV morphine	52	✔	red. ↓	red. ↓	imp r. ↑	/	3 or more rfx		M
D El Mallo et alii	ESPB + sham SAPB + 1g paracetamol IV 4x/d & ketorolac 30mg IV 3x/d + rescue 30mg IV tramadol	SAPB + sham ESPB + 1g paracetamol IV 4x/d & ketorolac 30mg IV 3x/d + rescue 30mg IV tramadol	50	✔	red. ↓	red. ↓	imp r. ↑	/	5(4-6), 5(3.5-6) median rfx	15%, 12% lung contusio ns	S
A Elawa ny et alii	ESPB + 1g acetaminophen IV 4x/d + rescue 0.1mg/kg morphine IV	PVB + 1g acetaminophen IV 4x/d + rescue 0.1mg/kg morphine IV	60	~	=	=	=	/	4.7(+1.2 8), 4.4(+1.1) mean rfx		S
S Singh et alii	ESPB + 10mg/kg ibuprofen IV + rescue 0.1mg/kg morphine IV	TEA + 10mg/kg ibuprofen IV + rescue 0.1mg/kg morphine IV	40	~	=	=	=	/	3.3, 3.4 mean rfx		M
S F Mostafa et alii	ESPB + 1g acetaminophen IV 4x/d + 30mg ketorolac IV 3x/d	TEA + 1g acetaminophen IV 4x/d + 30mg ketorolac IV 3x/d	60	~	=	=	=	/	4.6 (+1.27), 5.17 (+1.18) mean rfx		S
Nonpharmacological												
Abbas I et alii	Cryotherapy + IV dexketoprofen & IV fentanyl rescue	Refrigerated Saline Spray	100	✔	red. ↓	/	/	/	1-2 rfx		L
JP Slupe et alii	TENS + dihydrocodeine/p aracetamol 10mg/1g rescue	naproxen 250mg 3x/d + dihydrocodeine/p aracetamol 20mg/1g rescue	24	✔	=	/	imp r. ↑	/	3 or more		M
M Oncel et alii	TENS	inactive TENS plus naproxen PO/naproxen PO/oral placebo	100	✔	red. ↓	/	/	/	1-3 rfx		L
M Cabral et alii	Kinesiotaping + NSAIDs/paracetamol	NSAIDs/paracetamol + narcotics	46	✔	red. ↓	red. ↓	/	/	single rib fracture		L
AH Alica et alii	Kinesiotaping + flubiprofen	flubiprofen PO	30	✔	red. ↓	/	/	/	1-3 rfx		L
Ismail Dal	standard care (paracetamol 1000mg 3x/d, dexketoprofen 50mg 2x/d + tramadol 100mg rescue)	standard care	34	✔	red. ↓	/	/	=	mean 2.9 (+1.2), 3.4 (+1.2)	mean 7.4(+3.3), 6.4+2.5	L

L	lightly injured = 1-2 rfx and ISS<10
M	moderately injured = ISS 10-20 or rfx 3-5
S	severely injured = ISS> 20 or rfx over 5

✔	benefit compared to control group
~	equal results
✕	worse results compared to control group

and 16. No significant differences were found between groups in pain reduction, opioid consumption, respiratory function, or complication rates [13].

Intravenous lidocaine

Intravenous lidocaine has been associated with improved pain relief and significant reduction in opioid consumption, making it a valuable adjunct in multimodal pain management strategies. However, its effects on long-term outcomes, such as chronic pain and overall recovery after rib fractures, remained unchanged. *Patton* et al. observed reduced pain levels but no significant differences in IV opioids consumption or complications rates when comparing IV lidocaine to placebo. The study involved patients with a median of 5 and 6 rib fractures, and both groups received multimodal analgesia consisting of IV Paracetamol, NSAIDs,

and opioids [14].

Intravenous ketamine

Studies assessing the efficacy of IV ketamine as part of multimodal analgesia regimens have yielded mixed results.

- *Kugler* et al., in a subpopulation analysis, demonstrated that IV ketamine reduced opioid use in elderly patients with an ISS≥15, suggesting potential benefit in this subgroup. IV Ketamine was added to a standard regimen consisting of NSAIDs, paracetamol, opioids and rescue epidural analgesia, and compared to placebo with the same standard regimen. However, this opioid-sparing effect was not observed in the overall population, which had a median ISS of 13 and a mean of 6.3 rib fractures. Pain scores remained comparable across groups [15].
- *Carver* et al., similarly, found no significant differences in pain scores and opioid consumption in the general population (median 6.4 rib fractures, ISS 14), although a sub analysis of patients with ISS 15 showed a significant reduction in opioid consumption in the ketamine group. Both control and intervention groups used either IV ketamine or placebo, combined with the same standard regimen of NSAIDs, paracetamol, opioids, and rescue epidural analgesia [16].
- *Macheel* et al., in contrast, found no significant differences in opioid consumption or complication rates when IV ketamine was added to standard care compared to placebo. The standard regimen included paracetamol (1 g q.i.d), ibuprofen (600 mg q.i.d), ketorolac (7.5–15 mg IV q.i.d), lidocaine 5 % patches, oxycodone (5–10 mg 6 times daily) or hydromorphone (0.4–0.8 mg every 2 h), methocarbamol (500–1000 mg q.i.d), and optional rescue regional or epidural block. The study population had a mean of 5.7 and 7.12 rib fractures in the ketamine and placebo groups, respectively, and reported a statistically significant imbalance in ISS scores between groups (11.4 in placebo and 15.1 in ketamine) [17].

Adjunctive oral treatments

Abdelrahman et al. investigated the effect of adding oral melatonin compared to a placebo to a standard analgesic regimen consisting of epidural infusion, IV diclofenac (1 mg/kg, three times daily), IV paracetamol (1 g, three times daily), and rescue IV morphine (0.01mg/kg). Although pain levels were similar between groups, the melatonin one showed a reduction in opioid consumption. The study population had a mean of 3.175 and 3.2 rib fractures in the intervention and control groups, respectively [18].

Topical treatments

Four additional studies investigated the efficacy of topical treatment approaches, including two on lidocaine spray and two on lidocaine patches

- *Erdem* et al. compared 10 % lidocaine spray to IV opioids (tramadol or fentanyl), both paired with optional rescue IV tramadol and Intercostal nerve blocks (ICNB). No significant differences were observed in short-term pain relief (15,30, and 60 min), but opioid consumption was higher in the IV group. The population had a median of 2–3 rib fractures [19].
- *Dönmez* et al. studied lidocaine spray versus etofenamate or placebo spray, in conjunction with IV dexketoprofen and rescue IV tramadol. The study demonstrated no significant differences in pain relief or opioid consumption among the groups. Patients had 2–3 fractured ribs [20].
- *Ingalls* et al. compared two regimens containing IV opioids and paracetamol, combined with either lidocaine or placebo patches. In a population with a mean of 5.3 and 4.9 fractured ribs and mean ISS of 17.3 and 17.9, no significant differences were observed in pain levels, opioid consumption, or complication rates [21].
- Cheng et al., in contrast, found that lidocaine patches combined with oral tramadol/paracetamol significantly reduced pain and opioid consumption compared to placebo patches in patients with a mean of 3.04 and 3.0 rib fractures, respectively. However, no improvement in lung function was observed at the three-month follow-up [22].

These findings suggest that while topical treatments such as lidocaine sprays and patches show variable efficacy, opioid patches may represent a viable alternative in the management of rib fracture pain. Further research is required to clarify their broader clinical utility and integration into multimodal pain management protocols.

Neuraxial and regional anaesthesia

Epidural analgesia

Thoracic epidural analgesia (TEA) is widely regarded as the gold standard among regional approaches for managing pain associated with multiple rib fractures, particularly in cases involving three or more fractured ribs, flail chest, pulmonary contusion, or associated sternal fractures.

Seven RCTs, involving 303 patients, demonstrated that TEA significantly enhanced pain control, with varying results regarding respiratory function, opioid use and complication rates.

- *Bulger* et al. reported no overall difference in complication rates between TEA and IV opioids in patients with mean rib fracture counts of 7.2 and 6.8 rib and ISS of 26 and 25, respectively; however, when adjusted for pulmonary contusion, TEA significantly reduced complication rates [23].
- *Moon* et al. observed reductions in both pain levels and improvement in respiratory function when comparing TEA to IV PCA morphine in a population with 3 or more rib fractures and mean ISS of 26.6 and 23.4 [24].
- *Ullman* et al. found similar opioid consumption but better respiratory function (specifically tidal volume) in the TEA group compared to IV morphine in a population with mean rib fracture counts of 7.33 and 6.58 and ISS of 19.5 and 25.3 [25].
- *Ahmed* et al. demonstrated better respiratory function with TEA versus IV fentanyl in patients with mean rib fractures of 3.9 and 4.1 and ISS of 25 and 28, although this does not translate into a reduction of complication rates. However, a shorter hospital stay was recorded in the TEA group [26].
- *Heidari* et al. found a reduction in pain levels when comparing TEA to IV paracetamol (1 g) in a population with 3–4 rib fractures [27].
- *Luchette* et al. demonstrated a reduction in pain scores and opioid consumption, along with improved respiratory parameters, in patients receiving TEA compared to intrapleural blocks, both paired with IV morphine or meperidine. Patients had 3 or more unilateral rib fractures and mean ISS of 21.7 and 19.4 [28].
- *Kamali* et al. found reduced pain levels with TEA compared to intercostal blocks in a population with 3–4 rib fractures, but no significant difference in complication rates [29].

Paravertebral block

Paravertebral nerve blocks (PVB) serve as a viable alternative to epidural analgesia, offering effective pain relief with a potentially lower risk of systemic side effects. This technique involves the injection of local anaesthetics into the paravertebral space to target spinal nerves near their emergence. Evidence from multiple studies have shown the efficacy of paravertebral blocks in improving analgesia, reducing opioid consumption, and enhancing pulmonary function in patients with rib fractures. Although paravertebral block may be technically easier to perform than epidural blocks, they still pose challenges due to the anatomic proximity of the pleura and central neuraxial system.

We identified three RCTs evaluating thoracic paravertebral blocks as the intervention:

- *Yeying* et al. reported reduced pain scores, lower opioid consumption, and improved lung function comparing PVBs to IV sufentanil. Both groups received oral Paracetamol (500 mg twice daily) and rescue IV tramadol (1 mg/kg) in a population with mean of 3.9 and 4.1 rib fractures and mean ISS of 14.2 and 13.7, respectively [30].
- *Mohta* et al. found no significant differences when comparing PVB with and without fentanyl, both paired with intramuscular (IM) Diclofenac (1 mg/kg twice daily) and rescue IV morphine. The population had a mean of 4.1 and 3.9 rib fractures and mean ISS of 13.3 and 12.8 [31].
- *Mohta* et al. found similar reduction in pain, opioid consumption, improvement of respiratory function and complication rates when comparing PVB to TEA, both in combination with diclofenac IM (1 mg/kg) or tramadol IM (1 mg/kg) and rescue IV morphine. The mean number of rib fractures was 4.9 in both groups, with a mean ISS of 13.6 and 15.9 [32].

Intrapleural blocks

Intrapleural block is a regional analgesic technique involving the injection of local anaesthetic into the intrapleural space. Anaesthetic is absorbed by nerve endings in the pleura and further transported to nerve tissues.

We identified three trials that used intrapleural block as the intervention:

- *Gabram* et al. found no significant improvement in respiratory function or complications rates when comparing intrapleural catheter placement to IV opioid treatment alone. The study included a population with a mean of 3.4 and 4.4 rib fractures and ISS of 13.5 and 13.6 [33].
- *Short* et al. reported no significant benefit in pain scores, opioid use and respiratory function between intrapleural lidocaine and placebo injections, both paired with IV meperidine or morphine. Rib fracture count was not specified [34].
- *Shinohara* et al. conducted a prospective, randomised, crossover control study comparing intrapleural block to TEA, both paired with rescue IV butorphanol (1 mg). Pain levels, opioid consumption and complication rates were equal. Patients had a mean of 5.7 rib fractures [35].

Intercostal nerve block

Intercostal nerve blocks involve the injection of local anaesthetics near the intercostal nerves to provide targeted analgesia for fractured ribs. This technique is relatively simple to perform and is particularly effective for isolated rib fractures. However, the duration of analgesia is typically shorter compared to epidural or paravertebral nerve blocks, often necessitating repeated administrations or adjunctive therapies to maintain adequate pain control. In cases of multiple rib fractures, ICNBs must be performed at multiple levels, corresponding to the fractured ribs. This increases procedural complexity and the risk of complications, such as pneumothorax. Due to these limitations, the utility of intercostal nerve blocks in ED settings is limited.

The effect of ICNB was investigated in four trials:

- *Wallen* et al. found improvements in respiratory values but no significant differences in pain scores or opioid consumption in patients with a mean ISS of 17.76 and a mean number of fractured ribs of 7.28, comparing ICNB with a placebo injection. Both groups received standard care including Paracetamol, NSAIDs, transdermal lidocaine, IV/per os (PO) opioids, and epidural analgesia [36].
- *Ciftci* et al. reported significantly lower pain levels when intercostal blocks were added to oral analgesics (Paracetamol 500 mg 2x/day and celecoxib) compared to oral analgesics alone. Patients had a mean of 3.13 and 3.09 rib fractures in the respective groups [37].
- *Nasr-Esfahani et al.* found statistically significant improvements in both pain scores and opioid consumption when comparing ICNB to intrapleural analgesia. Both groups had potential rescue doses of IV fentanyl; rib fracture counts or ISS scores were not specified [38].
- *Hashemzadeh* et al. observed less effective pain relief and poorer respiratory function comparing ICNB to epidural analgesia, with possible pethidine rescue doses. However, there was no change in complication rates. Patients had 3 or more rib fractures [39].

Serratus anterior plane block (SAPB)

The serratus anterior plane block (SAPB) is a novel regional anaesthesia technique that provides targeted pain relief for rib fractures by anaesthetizing the lateral thoracic nerves within the serratus anterior plane. This method has been demonstrated to effectively reduce opioid consumption and enhance respiratory function, establishing its growing role in the management of thoracic trauma.

Its minimally invasive nature and relative ease of administration make it suitable also in ED setting [40]. We identified four trials investigating the analgesic effect of SAPB in patients with multiple rib fractures:

- *Teksen* et al., compared SAPB paired with IV PCA tramadol to IV PCA tramadol alone in a population with no information on the number of rib fractures and found statistically significant improvements in pain reduction and reduced opioid consumption [41].
- *Abu-Elwafa* et al. similarly found a reduction in pain levels and opioid consumption when comparing SAPB and IV morphine in a population with 3–6 rib fractures [42].
- *Partyka* et al. found a reduction in pain levels as well as opioid consumption, but equal complication rate when comparing a multimodal analgesic regimen with SAPB and without SAPB in a population with a median of 4 and 3 rib fractures and an AIS score of 1–2 in 92 patients and 3–5 in 115 patients [43].
- *Lunden* et al. underlined the limitations of SAPB when compared to epidural analgesia in severely injured patients with a mean of respectively 5 and 5 rib fractures and mean chest AIS scores of respectively 3 and 3. While it provided acceptable analgesia, it provided poorer reduction of pain levels, lower reduction of opioid consumption and less improvement of respiratory function. The complication rate was similar with the two approaches [44].

Erector spinae plane (ESP) block

The Erector Spinae Plane (ESP) block has gained increasing recognition as an effective regional anaesthesia technique for patients with multiple rib fractures. It consists in the injection of local anaesthetics into the fascial plane between the erector spinae muscle and the transverse processes of the thoracic vertebrae, resulting in extensive analgesia across the thoracic and abdominal walls.

This approach is emerging as effective option for multimodal analgesia, particularly in patients from whom more invasive techniques, such as epidural or paravertebral blocks, may not be feasible.

We found six trials investigating the effect of ESPB for pain management in multiple rib fractures:

- *Ramesh* et al. posed the question whether the effect of the ESPB could be explained by a placebo effect and compared ESPB to a sham procedure both in conjunction with standard analgesic care (1 g paracetamol IV 4x/d, ketorolac 30 mg IV 3x/day and rescue 50 mg IV tramadol). The study showed a strong reduction in pain scores measured on the NRS and an important decrease of opioid consumption in the intervention group compared to the placebo control group. Information on the number of rib fractures was not provided [45].
- *Elmansy* et al. reported reductions in both pain levels and opioid consumption, as well as improved pulmonary lung function, in patients with three or more unilateral rib fractures comparing ESPB with potential rescue doses of IV morphine to IV morphine alone [46].

- Similarly, *El Malla* et al. found comparable results when ESPBs were evaluated against SAPB in patients with a median of five fractured ribs. Both groups were paired with a sham procedure of their counterpart and IV Paracetamol and ketorolac [47].
- *Elawamy* et al. demonstrated equal outcomes in pain relief, opioid consumption, and pulmonary function when comparing ESPBs to thoracic paravertebral blocks paired both with 1 g of IV Paracetamol 4x/d and potential rescue doses of tramadol in patients with a mean of 4.73 and 4.43 fractured ribs [48].
- When comparing ESPB to thoracic epidural analgesia, *Singh* et al. observed similar pain levels, opioid consumption and respiratory improvement in a study involving patients with a mean of 3.3 and 3.4 fractured ribs. Both groups were given potential rescue doses of 0.1 mg/kg morphine [49].
- *Mostafa* et al. as well investigated the effect of ESPB in comparison to TEA both paired with 1 g Paracetamol IV 4x/day and 30 mg Ketorolac IV 3x/day in a population with 5.03 and 5.17 mean rib fractures respectively. The researchers found equal pain levels, opioid consumption and respiratory function improvements [50].

Nonpharmacological approaches

Cryotherapy

This technique reduces pain and inflammation by applying localised cooling to the injured area. It is particularly effective for rapid initial pain relief, making it a practical option in acute trauma settings.

We found one trial investigating cryotherapy in patients with rib fractures:

- *Akbas* et al. found a reduction in pain levels when comparing the effect of a cryotherapy spray to the effect of a refrigerated saline spray in a population with 1–2 rib fractures [51].

Transcutaneous electrical nerve stimulation (TENS)

TENS employs low-voltage electrical currents to modulate pain signalling pathways, providing a non-invasive and complementary approach to opioid-sparing analgesic protocols.

- *Oncel* et al. found a reduction in pain levels when comparing TENS with three control groups (inactive TENS plus naproxen, naproxen, oral placebo) in a population with 1–3 rib fractures [52].
- *Sloan* et al. showed no improvement in pain levels but an improvement in respiratory function when comparing TENS plus dihydrocodeine and paracetamol versus naproxen plus dihydrocodeine and paracetamol in a population with no further specified number of rib fractures [53].

Kinesiotaping

By offering mechanical support to the chest wall, kinesiotaping helps stabilize fractured ribs and alleviates pain during respiration, potentially improving functional outcomes.

A total of three studies were reviewed that investigated kinesiotaping.

- *Cakmak* et al. found a reduction in pain levels and opioid consumption when adding kinesiotaping to standard care (NSAIDs, Paracetamol) compared to only standard care in a population with single rib fractures [54].
- *Akca* et al. found a reduction in pain levels when comparing the addition of kinesiotaping to flurbiprofen versus flurbiprofen alone in a population with 1–3 rib fractures [55].
- *Dal* et al. found a reduction in pain levels comparing addition of kinesiotaping to standard care (IV Paracetamol 1 g 2x/day, dexketoprofen 50 mg 2x/day and rescue doses of 100 mg tramadol) that, however, did not translate into a lower rate of complications in a population with a mean of 2.9 and 3.4 rib fractures [56].

Discussion

Effective and timely pain management is paramount for patients with multiple rib fractures to prevent severe complications such as respiratory failure, pneumonia, and extended hospital stays. Most of the research on rib fracture analgesia highlights the importance of "multimodal analgesia", i.e., a method of managing pain that involves using several medications targeting different pain pathways to improve relief and reduce dependence on a single type of drug, thereby minimizing potential side effects. Although this concept has been declined in many ways across studies, a common theme is certainly present in the existing literature: the use of analgesic strategies that allow an opioid-sparing analgesia. Several reasons can explain why most clinicians and scientist consider of great value minimising opioid use. Firstly, besides causing common side effects such as nausea, vomiting, constipation or dry mouth, opioids can cause drowsiness, confusion, delirium and increase the risk of serious falls, especially in the elderly population [57, 58]. Secondly, opioids can induce respiratory depression and inhibit the reflex of cough, which are particularly undesirable side effects in patients with rib fractures. Thirdly, in-vitro, in-vivo as well as clinical studies suggest that opioids may induce immunosuppression, and in epidemiological studies, high doses and the initiation of opioid therapy for non-malignant pain have been correlated with a higher risk of infectious diseases such as pneumonia [59]. Since patients with multiple rib fractures are at high risk of developing pneumonia, it is important to minimise the use of drugs that may further increase this risk, as the incidence of pneumonia is associated with higher odds of mortality [60]. Fourthly, there is nowadays an increased awareness of the risk that opioid-naïve patients discharged from the hospital with a new opioid prescription can become long-term users [61]. Therefore, a judicious prescribing of analgesics in the acute phase of trauma can play a key role in preventing long-term use –and possibly misuse - of opioids.

Among the available strategies that allow an opioid-sparing effect in multiple rib fractures analgesia, the use of peripheral nerve blocks has gained momentum, due to the recent development of new techniques that seem to represent a valid alternative to thoracic epidural analgesia. The latter has been considered for a long time a gold standard approach to treat severe rib fracture pain, due to its excellent analgesic effect determining improved pulmonary function and minimising mechanical ventilation requirements. However, thoracic epidural requires advanced expertise and is contraindicated in patients with coagulopathy, sepsis or spinal deformities. Similarly, paravertebral block is associated with a high risk of complications and requires advanced technical skills and patient compliance. Emerging alternatives, particularly the ESP block and SAP block have shown promise due to their simplicity, ease of administration, effectiveness and safety profile, making them particularly suitable in all circumstances when epidural analgesia is contraindicated. Although these approaches were initially developed by anaesthetists in the context of thoracic surgery, they are increasingly being integrated in emergency medicine curricula along with other regional anaesthesia techniques, to deliver optimal multimodal analgesia in traumatic and non-traumatic pain at emergency departments [62,63]. Recent evidence from the United States suggest that ESP and SAP block are increasingly being used in emergency departments, and they are generally associated with a low incidence of adverse events [64]. However, procedure-specific complications and systemic effects such as local anaesthetic toxicity may occur and must be addressed during clinician training [65]. It remains unclear whether ESP block and SAP block provide equal analgesia in multiple rib fractures, or if either approach results in a clinically relevant superior analgesic effect, representing an important question to be addressed in future trials.

Similarly, future research should compare the safety, clinical and cost-effectiveness of continuous blocks delivered via catheters versus the use of single-shot blocks. Although the use of catheters can guarantee prolonged analgesia, it requires specific skills, is more resource consuming and is associated with higher risk of infections. The use of single-shot blocks, especially when performed using long-acting local anaesthetics and adjuvants (such as dexamethasone), can also guarantee prolonged analgesia [40] and is logistically easier to manage. Hence, it may represent a reasonable alternative, especially in context with low resources. Other regional techniques, such as the pectoralis nerve block (PECS) or parasternal blocks, have been described in the setting of thoracic trauma, especially when rib fractures are localised in the anterior chest and are associated with sternal fracture [66]. Nevertheless, their role in this setting is not clear as they have not been formally investigated in randomised trials.

Non-pharmacological interventions, such as cryotherapy, TENS and kinesiotaping, are increasingly being investigated as adjuncts to traditional analgesic strategies. These approaches offer non-invasive options with minimal side effects, making them particularly suitable for patients at high risk of opioid-related adverse events. However, the evidence to support these strategies is still limited. Therefore, further research is needed before they can be recommended in standard clinical care.

Certainly, one of the most unexplored areas of research remains the impact of acute analgesic strategies on long-term chronic pain, disability and quality of life. Evidence suggests that acute pain from traumatic injuries, including multiple rib fractures, can lead to the development of chronic pain, which can be predicted in the first few days following trauma [5,67]. Chronic pain can affect patients' quality of life and ability to work, also causing a significant economic burden for the society. For this scope, recent pioneering works on the use of intercostal nerve cryoneurolysis showed promising results that if confirmed in larger randomised trials may redefine the standard care of patients with multiple rib fractures [68,69].

Conclusion

Effective management of rib fracture pain in critical and emergency care requires balancing adequate analgesia with the minimization of complications. A multimodal, opioid-sparing approach that integrates systemic agents, regional anaesthesia, and non-pharmacological adjuncts emerges as the most effective strategy for improving patient outcomes. Among regional anaesthesia techniques, the ESP and SAP blocks represent promising, safe, and feasible alternatives to traditional epidural analgesia, particularly in these settings. Non-pharmacological options may provide additional benefit, although evidence remains limited. Future research should determine the comparative efficacy, safety, and cost-effectiveness of these modalities, and evaluate their long-term impact on chronic pain and disability. Such evidence will be pivotal to refining protocols and optimizing patient care in thoracic trauma, particularly rib fractures.

Declaration of generative AI and AI-assisted technologies in the writing process

During the preparation of this work, the authors used ChatCGPT to assist with English language editing. After using this tool, the authors reviewed and revised the content as necessary and take full responsibility for the final version of the manuscript.

Ethics statement

This article is a narrative review and does not involve any studies with human participants or animals performed by any of the authors.

CRediT authorship contribution statement

Thomas Ulrich Bresgen: Conceptualization, Writing – original draft, Investigation, Methodology, Visualization. **Francesco Salinaro:** Writing – review & editing, Writing – original draft. **Bruno Barcella:** Writing – original draft, Writing – review & editing. **Stefano Perlini:** Writing – original draft, Writing – review & editing. **Ilenia Mascherona:** Writing – review & editing, Project administration, Writing – original draft. **Santi Di Pietro:** Writing – review & editing, Visualization, Validation, Supervision, Project administration, Formal analysis, Conceptualization, Data curation, Investigation, Methodology, Writing – original draft.

Declaration of competing interest

The authors declare that they have no conflicts of interest related to this work.

Acknowledgements

All cited studies were fully reviewed, and key findings and conclusions were manually verified by the research team. Artificial Intelligence (AI) tools were used solely to enhance the quality of written English. No AI tools were employed to interpret study results, perform data analysis, or draw conclusions.

References

[1] Yamamoto L, Schroeder C, Morley D, Beliveau C. Thoracic trauma: the deadly dozen. Crit Care Nurs Q 2005;28(1):22–40. https://doi.org/10.1097/00002727-200501000-00004.
[2] Global Burden Of Disease Collaborative Network. Global Burden Of Disease Study 2021 (GBD 2021). Seattle, United States: Institute for Health Metrics and Evaluation (IHME); 2024.
[3] Peek J, et al. Traumatic rib fractures: a marker of severe injury. A nationwide study using the National Trauma Data Bank. Trauma Surg Acute Care Open 2020;5(1): e000441. https://doi.org/10.1136/tsaco-2020-000441.
[4] Battle C, et al. Predicting outcomes after blunt chest wall trauma: development and external validation of a new prognostic model. Crit Care Lond Engl 2014;18(3): R98. https://doi.org/10.1186/cc13873.
[5] Gordy S, Fabricant L, Ham B, Mullins R, Mayberry J. The contribution of rib fractures to chronic pain and disability. Am J Surg 2014;207(5):659–63. https://doi.org/10.1016/j.amjsurg.2013.12.012.
[6] Mukherjee K, et al. Non-surgical management and analgesia strategies for older adults with multiple rib fractures: a systematic review, meta-analysis, and practice management guideline from the Eastern Association for the Surgery of Trauma and the Chest Wall Injury Society. J Trauma Acute Care Surg 2023;94(3):398–407. https://doi.org/10.1097/TA.0000000000003830.
[7] Ho SW, et al. Risk of pneumonia in patients with isolated minor rib fractures: a nationwide cohort study. BMJ Open 2017;7(1):e013029. https://doi.org/10.1136/bmjopen-2016-013029.
[8] Peek J, Smeeing DPJ, Hietbrink F, Houwert RM, Marsman M, de Jong MB. Comparison of analgesic interventions for traumatic rib fractures: a systematic review and meta-analysis. Eur J Trauma Emerg Surg 2019;45(4):597–622. https://doi.org/10.1007/s00068-018-0918-7.
[9] Solak O, et al. The effectiveness of transdermal opioid in the management multiple rib fractures: randomized clinical trial. Balk Med J 2013;30(3):277–81. https://doi.org/10.5152/balkanmedj.2013.8191.
[10] Fulda GJ, Giberson F, Fagraeus l. A prospective randomized trial of nebulized morphine compared with patient-controlled analgesia morphine in the management of acute thoracic pain. J Trauma Inj Infect Crit Care 2005;59(2): 382–9. https://doi.org/10.1097/01.ta.0000179452.70520.1b.
[11] Esmailian M, Moshiri R, Zamani M. Comparison of the analgesic effect of intravenous acetaminophen and morphine sulfate in rib fracture; a randomized double-blind clinical trial. Emerg Tehran Iran 2015;3(3):99–102.
[12] Antill AC, et al. Treatment with oral versus intravenous acetaminophen in elderly trauma patients with rib fractures: a prospective randomized trial. Am J Surg 2020; 86(8):926–32. https://doi.org/10.1177/0003134820940268.
[13] Moskowitz EE, et al. A double-blind, randomized controlled trial of gabapentin vs. placebo for acute pain management in critically ill patients with rib fractures. Injury 2018;49(9):1693–8. https://doi.org/10.1016/j.injury.2018.06.002.
[14] Patton P, Vogt K, Priestap F, Parry N, Ball IM. Intravenous lidocaine for the management of traumatic rib fractures: a double-blind randomized controlled trial (INITIATE program of research). J Trauma Acute Care Surg 2022;93(4):496–502. https://doi.org/10.1097/TA.0000000000003562.

[15] Kugler NW, et al. Ketamine infusion for pain control in elderly patients with multiple rib fractures: results of a randomized controlled trial. J Trauma Acute Care Surg 2019;87(5):1181–8. https://doi.org/10.1097/TA.0000000000002479.
[16] Carver TW, et al. Ketamine infusion for pain control in adult patients with multiple rib fractures: results of a randomized control trial. J Trauma Acute Care Surg 2019; 86(2):181–8. https://doi.org/10.1097/TA.0000000000002103.
[17] Macheel C, Farhat J, Gipson J, Lindbloom P, West MA. No benefit from the addition of low-dose ketamine infusion to standard evidence-based care of patients with multiple rib fractures. J Trauma Acute Care Surg 2024;97(5):770–5. https://doi.org/10.1097/TA.0000000000004398.
[18] Abdelrahman AF, Omara AS, Elzohry AAM. Safety and efficacy of oral melatonin when combined with thoracic epidural analgesia in patients with bilateral multiple fracture ribs. Local Reg Anesth 2020;13:21–8. https://doi.org/10.2147/LRA.S244510.
[19] Erdem AB, Donmez S, Sener A. Comparison of the analgesic efficacy of lidocaine spray versus Tramadol and Fentanyl for pain control in rib fractures. J Coll Physicians Surg Pak 2023;33(5):491–7. https://doi.org/10.29271/jcpsp.2023.05.491.
[20] Dönmez S, Erdem AB, Şener A, Altas F, Mutlu RI. Placebo-controlled randomized double-blind comparison of the analgesic efficacy of lidocaine spray and etofenamate spray in pain control of rib fractures. Ulus Travma Acil Cerrahi Derg 2023;29(8):929–34. https://doi.org/10.14744/tjtes.2023.40652.
[21] Ingalls NK, Horton ZA, Bettendorf M, Frye I, Rodriguez C. Randomized, double-blind, placebo-controlled trial using lidocaine patch 5% in traumatic rib fractures. J Am Coll Surg 2010;210(2):205–9. https://doi.org/10.1016/j.jamcollsurg.2009.10.020.
[22] Cheng YJ. Lidocaine skin patch (Lidopat® 5%) is effective in the treatment of traumatic rib fractures: a prospective double-blinded and vehicle-controlled study. Med Princ Pract Int J Kuwait Univ Health Sci Cent 2016;25(1):36–9. https://doi.org/10.1159/000441002.
[23] Bulger EM, Edwards T, Klotz P, Jurkovich GJ. Epidural analgesia improves outcome after multiple rib fractures. Surgery 2004;136(2):426–30. https://doi.org/10.1016/j.surg.2004.05.019.
[24] Moon MR, et al. Prospective, randomized comparison of epidural versus parenteral opioid analgesia in thoracic trauma. Ann Surg 1999;229(5):684–91. https://doi.org/10.1097/00000658-199905000-00011.
[25] Ullman DA, Fortune JB, Greenhouse BB, Wimpy RE, Kennedy TM. The treatment of patients with multiple rib fractures using continuous thoracic epidural narcotic infusion. Reg Anesth 1989;14(1):43–7.
[26] Ahmed SM, Athar M, Ali S, Doley K, Siddiqi OA, Usmani H. Acute pain services in flail chest-a prospective randomized trial of epidural versus parenteral analgesia in mechanically ventilated ICU patients. Egypt J Anaesth 2015;31(4):327–30. https://doi.org/10.1016/j.egja.2015.06.001.
[27] Heidari S. Comparison of epidural block and apotel in controlling pain among patients with rib fracture. Int J Pharm Res 2019;11(2):52–4. https://doi.org/10.31838/ijpr/2019.11.02.054.
[28] Luchette FA, Radafshar SM, Kaiser R, Flynn W, Hassett JM. Prospective evaluation of epidural versus intrapleural catheters for analgesia in chest wall trauma. J Trauma 1994;36(6):865–9. https://doi.org/10.1097/00005373-199406000-00018. discussion 869-870.
[29] Kamali A, Broujerdi G, Bagheri H. Comparing epidural block and intercostal block in patients with 3-4 broken ribs following chest cage blunt trauma. Ann Trop Med Public Health 2017;10(4):850. https://doi.org/10.4103/ATMPH.ATMPH_197_17.
[30] Yeying G, et al. Thoracic paravertebral block versus intravenous patient-controlled analgesia for pain treatment in patients with multiple rib fractures. J Int Med Res 2017;45(6):2085–91. https://doi.org/10.1177/0300060517710068.
[31] Mohta M, Ophrii EL, Sethi AK, Agarwal D, Jain BK. Continuous paravertebral infusion of ropivacaine with or without fentanyl for pain relief in unilateral multiple fractured ribs. Indian J Anaesth 2013;57(6):555–61. https://doi.org/10.4103/0019-5049.123327.
[32] Mohta M, Verma P, Saxena AK, Sethi AK, Tyagi A, Girotra G. Prospective, randomized comparison of continuous thoracic epidural and thoracic paravertebral infusion in patients with unilateral multiple fractured ribs–a pilot study. J Trauma 2009;66(4):1096–101. https://doi.org/10.1097/TA.0b013e318166d76d.
[33] Gabram SG, et al. Clinical management of blunt trauma patients with unilateral rib fractures: a randomized trial. World J Surg 1995;19(3):388–93. https://doi.org/10.1007/BF00299166.
[34] Short K, Scheeres D, Mlakar J, Dean R. Evaluation of intrapleural analgesia in the management of blunt traumatic chest wall pain: a clinical trial. Am Surg 1996;62(6):488–93.
[35] Shinohara K, Iwama H, Akama Y, Tase C. Interpleural block for patients with multiple rib fractures: comparison with epidural block. J Emerg Med 1994;12(4): 441–6. https://doi.org/10.1016/0736-4679(94)90337-9.
[36] Wallen TE, et al. Intercostal liposomal bupivacaine injection for rib fractures: a prospective randomized controlled trial. J Trauma Acute Care Surg 2022;92(2): 266–76. https://doi.org/10.1097/TA.0000000000003462.
[37] Ciftci H, Gezginaslan O. The effectiveness of intercostal nerve block on return to work, quality of life, and hand grip strength in patients with isolated rib fractures: a single-blind, randomized controlled study. J Surg Stud 2025;(SUPPL 1). Available from: https://acikerisim.sbu.edu.tr/yayin/26447.
[38] Nasr-Esfahani M, Kolahdouzan M, Pourazari P, Yazdani E. Comparing the effectiveness of bupivacaine administration through chest tube and intercostal blockage in patients with rib fractures. Adv Biomed Res 2022;11:66. https://doi.org/10.4103/abr.abr_50_21.
[39] Hashemzadeh S, Hashemzadeh K, Hosseinzadeh H, Aligholipour Maleki R, Golzari SEJ. Comparison thoracic epidural and intercostal block to improve ventilation parameters and reduce pain in patients with multiple rib fractures. Cardiovasc Thorac Res 2011;3(3):87–91. https://doi.org/10.5681/jcvtr.2011.019.
[40] Di Pietro S, Mascia B, Perlini S, Iotti GA. Levobupivacaine combined with dexamethasone for serratus plane block can provide long-lasting analgesia in multiple rib fractures. Emerg Care J 2019;15(1):10. https://doi.org/10.4081/ecj.2019.7716.
[41] Tekşen Ş, et al. Analgesic efficacy of the serratus anterior plane block in rib fractures pain: a randomized controlled trial. Am J Emerg Med 2021;41:16–20. https://doi.org/10.1016/j.ajem.2020.12.041.
[42] Abu-Elwafa WAEG, Ragab IA, Abdelrahman AH, Mahmoud WA. Comparative study between efficacy of serratus anterior muscle block as a regional analgesia technique and I.V morphine infusion in patient with fracture ribs. Egypt J Hosp Med 2022;82(2):348. https://doi.org/10.21608/ejhm.2021.144900. -252.
[43] Partyka C, et al. Serratus anterior plane blocks for early rib fracture pain management: the SABRE randomized clinical trial. JAMA Surg 2024;159(7):810–7. https://doi.org/10.1001/jamasurg.2024.0969.
[44] Lundén AR, Tarkkila P. An ultrasound-guided serratus anterior plane block with continuous local anaesthetic infusion and epidural analgesia for rib fracture pain. Acta Anaesthesiol Scand 2024;68(3):394–401. https://doi.org/10.1111/aas.14355.
[45] Ramesh S, Ayyan SM, Rath DP, Sadanandan DM. Efficacy and safety of ultrasound-guided erector spinae plane block compared to sham procedure in adult patients with rib fractures presenting to the emergency department: a randomized controlled trial. Acad Emerg Med 2024;31(4):316–25. https://doi.org/10.1111/acem.14820.
[46] Elmansy S, Abdelkhalek M, Farouk S, Shoukry R, Khames S. Ultrasound -guided erector spinae plane block (ESPB) versus intravenous opioids based analgesia in patients with rib fractures. Egypt J Anaesth 2023;39(1):249–54. https://doi.org/10.1080/11101849.2023.2188729.
[47] El Malla DA, Helal RAEF, Zidan TAM, El Mourad MB. The effect of erector spinae block versus Serratus plane block on pain scores and diaphragmatic excursion in multiple rib fractures. A prospective randomized trial. Pain Med 2022;23(3): 448–55. https://doi.org/10.1093/pm/pnab214.
[48] Elawamy A, Morsy MR, Ahmed MAY. Comparison of thoracic erector spinae plane block with thoracic paravertebral block for pain management in patients with unilateral multiple fractured ribs. Pain Physician 2022;25(6):483–90.
[49] Singh S, Avinash R, Jaiswal S, Kumari A. Comparison of safety and efficacy of thoracic epidural block and erector spinae plane block for analgesia in patients with multiple rib fractures: a pilot single-blinded, randomised controlled trial. Indian J Anaesth 2023;67(7):614–9. https://doi.org/10.4103/ija.ija_844_21.
[50] Mostafa SF, Eid GM. Ultrasound guided erector spinae plane block versus thoracic epidural analgesia in traumatic flail chest, a prospective randomized trial. J Anaesthesiol Clin Pharmacol 2023;39(2):250–7. https://doi.org/10.4103/joacp.joacp_416_21.
[51] Akbaş İ, et al. Effect of coolant spray on rib fracture pain of geriatric blunt thoracic trauma patients: a randomized controlled trial. Rev Assoc Med Bras 2023;69(1): 30–6. https://doi.org/10.1590/1806-9282.20220048.
[52] Oncel M, Sencan S, Yildiz H, Kurt N. Transcutaneous electrical nerve stimulation for pain management in patients with uncomplicated minor rib fractures. Eur J Cardiothorac Surg 2022;22(1):13–7. https://doi.org/10.1016/s1010-7940(02)00206-3.
[53] Sloan JP, Muwanga CL, Waters EA, Dove AF, Dave SH. Multiple rib fractures: transcutaneous nerve stimulation versus conventional analgesia. J Trauma 1986;26(12):1120–2. https://doi.org/10.1097/00005373-198612000-00012.
[54] Cakmak M, Aydin S, Balci AE. The comparison of analgesics and kinesiological taping in rib fractures. Indian J Surg 2021;83(1):190–4. https://doi.org/10.1007/s12262-021-02856-5.
[55] Akça AH, Şaşmaz MI, Kaplan Ş. Kinesiotaping for isolated rib fractures in emergency department. Am J Emerg Med 2020;38(3):638–40. https://doi.org/10.1016/j.ajem.2019.11.049.
[56] Dal İ, Bektaş Ö, Kader S, Bodur G. Can kinesiotaping reduce pain in rib fractures?: a randomized prospective study. J Pain Res 2024;17:4239–47. https://doi.org/10.2147/JPR.S500974.
[57] Hopkins RE, et al. Age-related risk of serious fall events and opioid analgesic use. JAMA Intern Med 2024;184(4):394–401. https://doi.org/10.1001/jamainternmed.2023.8154.
[58] Clegg A, Young JB. Which medications to avoid in people at risk of delirium: a systematic review. Age Ageing 2011;40(1):23–9. https://doi.org/10.1093/ageing/afq140.
[59] Plein LM, Rittner HL. Opioids and the immune system - friend or foe. Br J Pharmacol 2018;175(14):2717–25. https://doi.org/10.1111/bph.13750.
[60] Brasel KJ, Guse CE, Layde P, Weigelt JA. Rib fractures: relationship with pneumonia and mortality. Crit Care Med 2006;34(6):1642–6. https://doi.org/10.1097/01.CCM.0000217926.40975.4B.
[61] Barnett ML, Olenski AR, Jena AB. Opioid-prescribing patterns of emergency physicians and risk of long-term use. N Engl J Med 2017;376(7):663–73. https://doi.org/10.1056/NEJMsa1610524.
[62] Di Pietro S, et al. Comparing the pericapsular nerve group block and fascia iliaca block for acute pain management in patients with hip fracture: a randomised clinical trial. Anaesthesia 2024;79(na). https://doi.org/10.1111/anae.16695. na.
[63] Di Pietro S, Caracciolo E, Barcella B, Perlini S. Regional anaesthesia in emergency medicine research group. Superficial cervical plexus block in emergency departments: rationale for its use in incision and drainage of neck skin abscesses. Intern Emerg Med 2022;17(5):1533–6. https://doi.org/10.1007/s11739-022-02992-0.

[64] Goldsmith A, et al. Complication rates after ultrasonography-guided nerve blocks performed in the emergency department. JAMA Netw Open 2024;7(11):e2444742. https://doi.org/10.1001/jamanetworkopen.2024.44742.
[65] Lago E, et al. Local anaesthetic toxicity syndrome: can posters illustrating the treating algorithm improve medical management? Intern Emerg Med 2023;18(7): 2149–50. https://doi.org/10.1007/s11739-023-03406-5.
[66] Di Pietro S, Mascia B, Lo Bianco G, Perlini S, Iotti GA. Anterior cutaneous nerve block for analgesia in anterior chest trauma: is the parasternal approach necessary? Clin Exp Emerg Med 2020;7(1):67–70. https://doi.org/10.15441/ceem.18.089.
[67] Evans DW, et al. Estimating risk of chronic pain and disability following musculoskeletal trauma in the United Kingdom. JAMA Netw Open 2022;5(8): e2228870. https://doi.org/10.1001/jamanetworkopen.2022.28870.
[68] Finneran JJ, et al. Ultrasound-guided percutaneous cryoneurolysis for the treatment of pain after traumatic rib fracture: a randomized, active-controlled, participant- and observer-masked study. Anesthesiology 2025;142(3):532–45. https://doi.org/10.1097/ALN.0000000000005328.
[69] Forrester JD, et al. Ultrasound-guided percutaneous cryoneurolysis of intercostal nerves in traumatic rib fractures. Injury 2025;56(5):112321. https://doi.org/10.1016/j.injury.2025.112321.